

# Gynaecological complications of leech bite.

Siew Cheng CHAI<sup>1</sup>, Wan Azman WAN SULAIMAN<sup>1</sup>, Ahmad Amir ISMAIL<sup>2</sup>

<sup>1</sup>Reconstructive Sciences Department, School of Medical Sciences, Universiti Sains Malaysia, Kubang Kerian, Kelantan 16150, Malaysia

<sup>2</sup>Obstetrics and Gynecology department, School of Medical Sciences, Universiti Sains Malaysia, Kubang Kerian, Kelantan 16150, Malaysia

## ABSTRACT

In tropical countries, leech bites are common and reported to cause life-threatening complications. We would like to highlight two cases that represented acute and chronic gynaecological complications of leech bites. First case was a two-year-old girl who presented with persistent vaginal bleeding complicated by disseminated intravascular coagulopathy after a leech was forcefully removed from her introitus. Second case was a 15-year-old girl who presented with a history of progressive difficulty and incomplete micturition three years after an incident with a leech bite at the vulva region. She was noted to have complete midline fusion of her labia minora with a pinhole orifice, which required surgical intervention. These two cases highlights the acute and chronic complications that can arise from such a simple leech bites which can be life threatening. Awareness of such potential complications of leech bites will lead to early referral and early treatment.

**Keywords:** leech bite, vaginal bleeding, labial fusion, Z-plasty

## INTRODUCTION

Leeches are blood-sucking hermaphroditic parasites that belong to phylum Annelida of class Hirudinea. Leeches suck the blood without causing pain by using three sharp teeth located in the upper jaw. The presence of hirudin as the anticoagulant agent in the leech's saliva may lead the wound to have persistent bleeding for hours.<sup>1</sup>

Leeches are generally not harmful to humans when bites are external. However, once they invade through human body orifices while swimming in the river or using contaminated water, they can cause significant morbidities. Leech bites to the nose, pharynx, urethra, bladder and rectum had been reported.<sup>2-4</sup>

Vaginal bleeding due to leech bites is uncommon.<sup>4-5</sup> Moreover, no literature has ever reported chronic complications of leech bites. In this report, we discussed two cases, which presented as acute and chronic complications of leech bites, and their respective treatments.

## CASE REPORT

### Case 1

A two-year old girl was noted to have a leech bite at her vagina after playing in the flood-water. The leech was hooked to the vaginal wall while its tail was dangling off the introitus. Inadvertently, the leech was pulled off forcefully causing persistent bleeding in the vagina. She was presented to the Emergency Department approximately two hours later due to difficulty in getting transport at the remote area. Clinically, she was pale albeit vital

**Correspondence author:** Chai Siew Cheng  
Reconstructive Sciences Unit, School of Medical Sciences, Health Campus Universiti Sains Malaysia, 16150 Kubang Kerian Kelantan  
Phone No: 609-7676000  
Email: scchai513@gmail.com

signs were recorded as stable. Since bleeding was imminent, she lost an estimated 200ml of blood which resulted in a drop of haemoglobin to 7g/dl. Examination under anaesthesia and vaginal irrigation with normal saline was carried out. Bleeding was controlled after first irrigation but unfortunately recurred after five hours. She was then brought back to operation theatre and noted to have persistent bleeding which was complicated with disseminated intravascular coagulopathy (DIC) with low platelet count ( $6 \times 10^9/L$ ) and deranged coagulation profile (PT 18.4, aPTT 56.3). Bleeding was eventually stopped with irrigation and vaginal packing, while the DIC was corrected with fresh frozen plasma. Total estimated blood loss was 600ml. Patient was transfused with a total of 48ml/kg of packed cells and 300ml of fresh frozen plasma. Antibiotic was administered. She was well at day four of hospitalisation, and then was discharged.

#### Case 2

A 15-year old girl was presented with a history of difficulty in urinary voiding for three years. Her history of presentation started after an episode of a leech bite at the labial region at the age of 12 years. Following the removal of the leech, an active bleeding from the affected area ensued but ceased spontaneously. Subsequently, she started to experience difficulty in passing urine but had been concealing the symptoms from her parents until it worsened. She attained menarche at the age of 11 and had regular menstrual periods. There was no other history of genital procedure, genital trauma or recurrent infection over the groin region after the incident of leech bite.

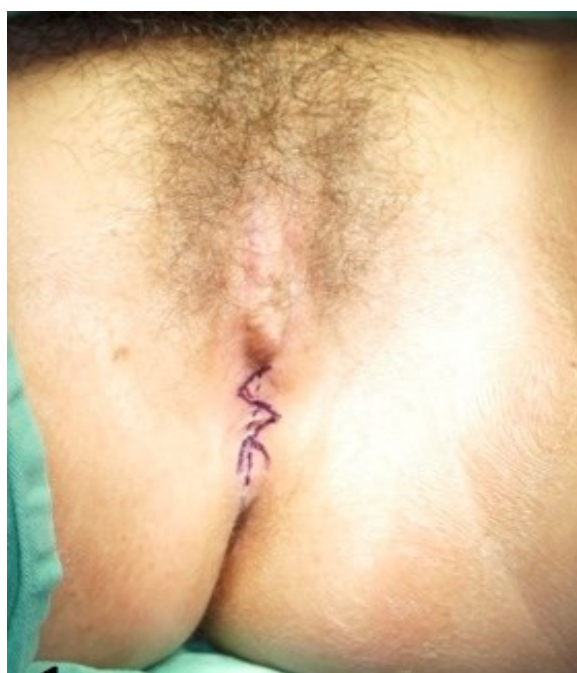
On pelvic examination, a complete midline fusion of labia minora was seen, with only a pinhole opening for passage of urine and menses. Urethral and vaginal opening were not assessable. Trans-abdominal ultrasound revealed insignificant findings of ova-

ries and uterus.

Case was subsequently referred to a plastic surgery team for reconstructive management. Surgical labial separation was performed (Figure 1). Separation was done with multiple Z-plasty technique. On day 1 post-operation, urinary bladder catheter was removed and the patient was subsequently able to pass urine smoothly. Upon a clinical follow-up after three months, she had no obstructive urinary symptoms. Her labia minora is well separated and poised with a natural-looking structure. Part of the tissue from the fusion labia minora was sent for histopathology examination and mainly revealed fibrotic tissue.

#### Discussion

Leech bite is a rare cause for vaginal bleeding, but should be kept in mind; especially in tropical countries. Proper history is of utmost importance for diagnosis because in majority of cases, the leech is removed or has migrated prior to arrival to the hospital. A history of swimming in the river, ponds, swamps, flood-water or using contaminated water prior to



**Figure 1: Fusion of labial minora with one small orifice, both urethral and vaginal opening were covered. Pre-operative Z-plasty was planned.**

the onset of bleeding may suggest underlying leech bites.

In terms of on-site treatment, removal of the leech by putting salt or normal saline was reported to be effective. The leech may detach from the bite due to loss of body water in hypertonic milieu.<sup>2,4</sup> Other described methods of leech removal include the use of glycerine phenice,<sup>3</sup> injection of lignocaine to paralyse the leech<sup>5</sup> and application of vinegar. Leeches should not be removed forcefully as their jaws may remain in the wound and become a nidus of infections.<sup>6</sup> Moreover, injury to the fragile tissue, for instance at the vaginal wall, can lead to profuse bleeding (Case 1) and 'secondary' tissue inflammation with fusion of raw area of both sides of the labia (Case 2). Bleeding caused by leech bites will usually stop spontaneously. Persistent bleeding after leech bites can be attributed to several reasons: first, due to hirudin from its saliva, which acts as an anticoagulant by inhibiting factor IXa and thrombin in the coagulation chain. Hyaluronase and calin are also present in the leeches' saliva and possess similar anticoagulant property. Bleeding can be persistent for up to 10 hours to seven days.<sup>1,3</sup> Secondly, migration of the leech to deeper tissue structure may lead to bleeding complications. Thirdly, consequent disseminated intravascular coagulopathy as a secondary complication is due to significant blood loss; as what had occurred in our patient (first case).

To the best of our knowledge, there is no report on the chronic complications of leech bites yet. Leech bites cause small wounds, which will usually heal without much complications. However, proper wound care at the genitalia region is indicated because of its moist environment that poses higher risk for secondary infections and inflammation. As in our patient (second case), labial fusion could be due to the intense inflammation and infection that had occurred.

Labial fusion commonly involves pre-pubertal and postmenopausal women due to hypoestrogenic status. Majority of patients respond to estrogen cream for separation. In comparison with our patient, the labial fusion involved intense fibrosis and surgical intervention. Surgical separation was carried out with Z-plasty technique as single step surgery. Z-plasty closure helped in scar lengthening and prevention of scar contracture. Secondly, it keeps reconstructed labia minora slightly apart to reduce the risk of fusion. In comparison with previous literatures, adhesiolysis was carried out without sharp dissection by using Hegar's dilator and curved forceps in an advancing and expanding manner.<sup>7-8</sup> This method is not suitable for patients with dense fibrosis which carry higher risk for scar contracture and re-fusion post operation.

In conclusion, Leech bites can lead to potential acute and chronic complications. Doctors working in rural areas should be aware of them. Diagnosis and treatment must be promptly carried out to prevent secondary complications from leech bites. Tertiary hospital referral should be done with no delay in acute cases.

## References

- 1: Eldor A, Orevi, Rigbi M. The role of the leech in medical therapeutics leech. *Blood rev* 1996;10:201-9.
- 2: Hamid MSA, Mohd Nor GR. Severe urological complication of leech bite in the tropic. *Br J Urol* 1996;77:164-5.
- 3: Nerges Askari, Afrooz Eshagnian. Otorrhagia bleeding due to leech bite. *Adv Biomed Res* 2012;1;15.
- 4: Jafrul Hannan, Mozammel Hoque. Leech infestation in children through body orifices: Experience in a Hospital in Bangladesh. *World J Surg* 2012;36:2090-2.
- 5: M Hasanzadeh Mofrad, R Shafiei, S Bolandi, M Najjari, GR Hatam. Leech bite: A rare cause of postmenopausal vaginal bleeding. *Iran Red Crescent Med J* 2012;14(6):384-5.
- 6: Adams LA. The emergency management of medicinal leech bite. *Ann Emerg Med* 1989;18:316-19.
- 7: Yasuyuki Hatada. Two step surgical approach to labial adhesion in postmenopausal woman. *Acta Obstet Gynecol Scand* 2003;82:1054-5.
- 8: Imamura R, Fujimoto M, Meguro N, Maeda O, Saiki S, Kinouchi T, et al. Labial adhesion presenting as urinary incontinence and dysuria in postmenopausal woman: a case report.